Manipal Alumni Science and Health Journal 2023; 8(1): 2

# Keningau Weave Technique: A modification Of The Japanese "Himawari" Method For Comminuted Patella Fixation

Eyrique G[1], Jeremy SV[2], Vickneshan S[3], Amir R[3], Looi C[4]

*Corresponding Author Email: eyrique.goh.boay.heong@gmail.com*

## ABSTRACT

Severely comminuted patella fractures deemed unsalvageable have traditionally been treated with patellectomies. This procedure significantly reduces the mechanical advantage the patella provides to the quadriceps for knee extension resulting in significant morbidity. The 'Himawari Method' developed in Japan has significantly reduced the need to resort to patellectomies. However, this procedure requires the use of expensive locking sleeves to be successful. The modified technique illustrated here excluded the need for the locking sleeves by weaving cerclage wires around multiple longitudinal k-wires creating an anterior cage over the patella. With the addition of a tension relieving wire, the efficacy of the modified procedure as the patient achieved fracture union with full range of motion at 12 weeks can be demonstrated. Outcome evaluated utilizing the patellar-femoral instability scorings, Favourable Kujala patellar instability scores & Oxford knee score were noted a year post-intervention.

[1] Orthopaedics & Traumatology, Hospital Kuala Lumpur, Kuala Lumpur, Malaysia
[2] Orthopaedics & Traumatology, Hospital Queen Elizabeth 1, Kota Kinabalu, Sabah, Malaysia
[3] Orthopaedics & Traumatology, Hospital Keningau, Keningau, Sabah, Malaysia
[4] Dept of Orthopedics, Faculty of Medicine and Health Sciences, University Putra Malaysia, Serdang, Malaysia

## INTRODUCTION

Patella fractures encompass about 1 percent of skeletal fractures and are prevalent between the ages of 20–50 years. [4,5]. The mechanism of these fractures is usually a result of direct impact or eccentric contraction. [4] It causes excruciating pain and results in significant disability as it is pivotal in the knee extension mechanism.[6]

There are several fixation methods for unstable patellar fractures, namely tension band wiring, cerclage wiring, and screw fixation or combinations of the aforementioned as opposed to the stable fractures that can be treated conservatively with a cylinder cast. Fractures of the patella require anatomical reduction of the articular surface with a rigid fixation. This helps to restore the extensor mechanism and allows early mobilization.

Patellectomies have been utilized in cases with severe comminution where reduction and stabilization are not feasible. However, several studies have confirmed poor clinical outcome due to the patella's role in providing mechanical advantage to the quadriceps by altering its moment arm [5,6]. Therefore, this procedure should be reserved as a last resort.[7] All efforts at reconstruction should be considered, even in severely displaced or comminuted fractures prior to patellectomy.

## CASE DESCRIPTION

A 15 year old boy involved in a motor-vehicle accident, sustained an open comminuted fracture of the right patella (figure 1) with other associated polytraumatic fractures.

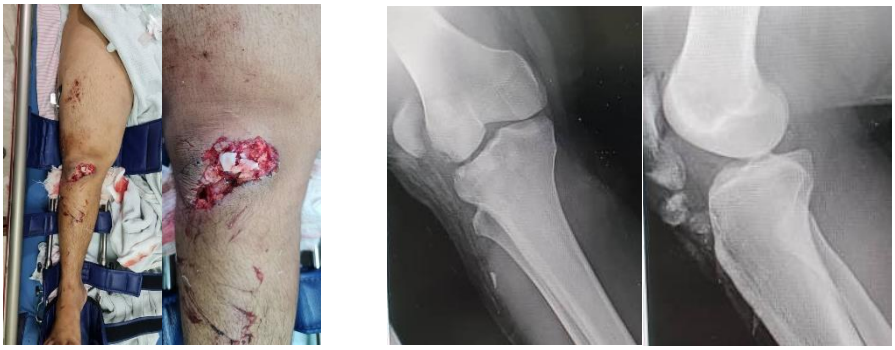

a) b)

Figure 1.
a) Post trauma, open fracture right patella – with exposed patella bone fragment.
b) Plain radiograph of the right knee: Comminuted patella fracture with no fractures of the distal femur or tibia plateau.

An emergent surgical debridement and fixation of the fractured patella was performed. Intraoperatively, a severely comminuted patella fracture with bone loss was noted. A thorough debridement and surgical washout of the knee joint was performed prior to patella fixation using a modified Himawari technique. The modification via stellate k wires around the patella with weaving cerclage to emulate a locking mechanism was performed as a rigid fixation across the patella. Detailed description of the technique is covered in the surgical technique section below. Surgery was uncomplicated, fixation was stable throughout the range of motion – Stability was checked intraoperatively post fixation under direct visualization and confirmed with an image intensifier guidance. Post-operative check x-rays are shown as in (figure 2).

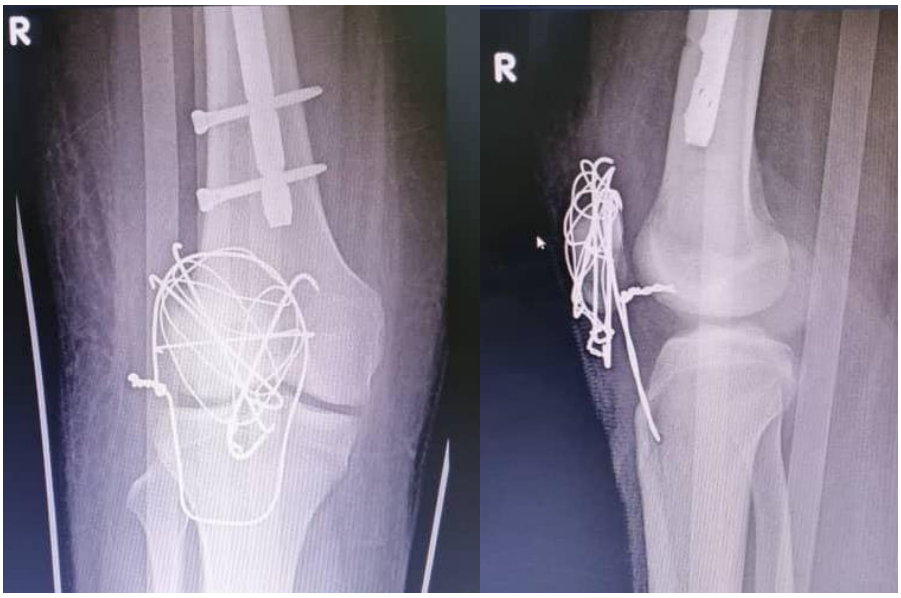

Figure 2: Post operative check radiograph – patella fixation with a tension relieving wire.

The patient recovered well and commenced early ROM exercises with non-weight-bearing ambulation, in view of the closed right midshaft femur fracture (fixed with an interlocking nail). He was reviewed monthly, the wound healed well with good passive ROM of the right knee ranging 0-60 (with the TRW) as shown in (figure 2). The tension relieving wire was removed 6 weeks post-surgery (figure 5). Patient continued his physiotherapy and started partial weight bearing ambulation.

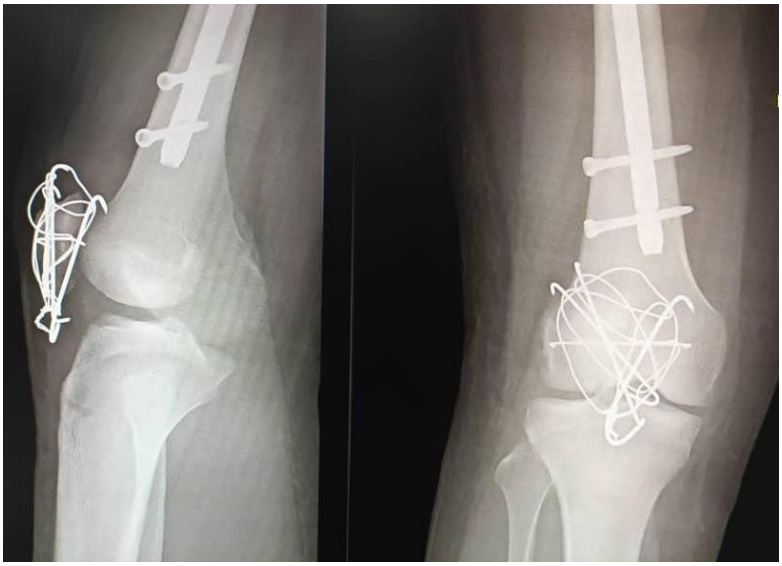
Figure 3: Post patella fixation 6 weeks with removed TRW

Patient was subsequently followed up in 2 months, was able to ambulate without assistance with no other active complaints. Active ROM of right knee was 0 – 130. Removal

of implants over right knee were performed, which will be described too in the surgical section below. Post removal of implant (figure 4 and 5), patient was able to ambulate normally and was able to achieve ROM of 0 – 130 on active flexion of right knee.

Figure 4: Post removal of patella fixation implant

Figure 5: Patients ability for near normal ROM.

Patient had been followed up until a year post surgery for assessment of his patellar stability. Patient had near normal range of motion over the knee with good outcome scoring using knee scoring systems. Patient was scored with both Kujala patella instability scoring & Oxford knee scoring which are near physiological normal.

- Oxford knee score: 48/48 (excellent)
- Kujala knee score: 94/100 (good)

**The Original "Himawari" Surgical Method**

The patient is placed supine on the operating table and a midline approach is utilized to approach the fracture. fragments are reduced and held with multiple k-wires. locking sleeves are then placed on these k wires and a cerclage wire is passed through their holes. The free end of the cerclage wire is then passed anterior to the patella to the opposing sleeve several times to create anterior mesh for anterior stability. Once the construct is complete the sleeves are crimped to secure the cerclage in place.

**Surgical Technique: Keningau Weave**

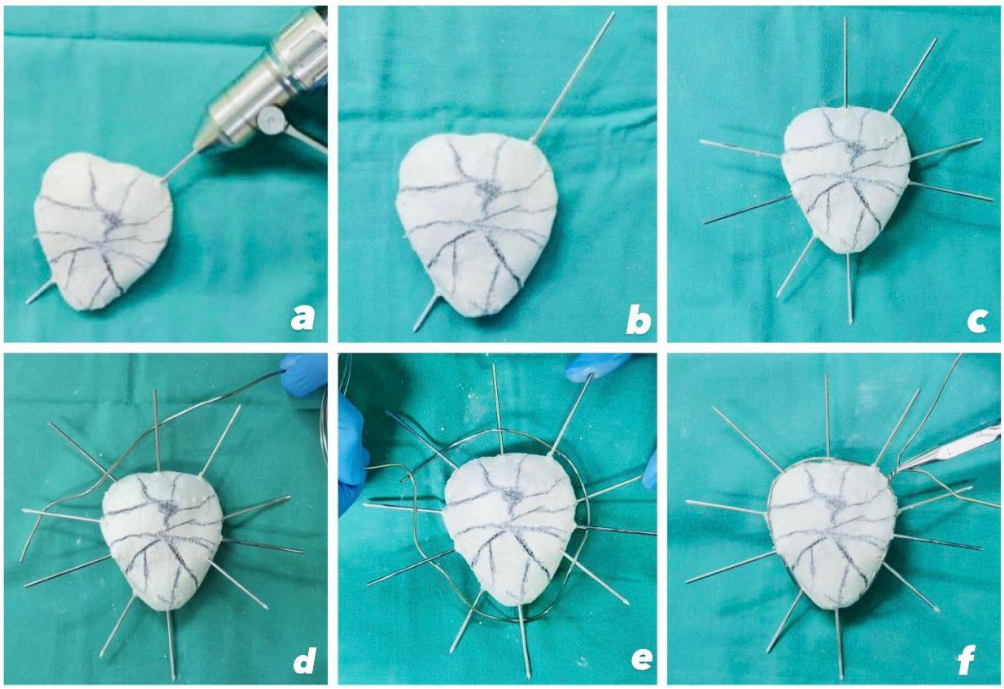


Figure 6

a) Fragments are reduced using a pointed reduction forceps. Reduction in extension
b) Drill a k wire 1.6 - 1.8mm through the patella stabilizing 2 fragments.
c) Several other k wires inserted across the patella as above stabilizing remaining fragments.
d) A cerclage wire (1.4mm) is weaved around the k wire entry and exit point along the patella rim
e) Cerclarge wire weaves alternate anterior and posteriorly to the wire entry and exits.
f) Tighten the circumferential wire by twisting

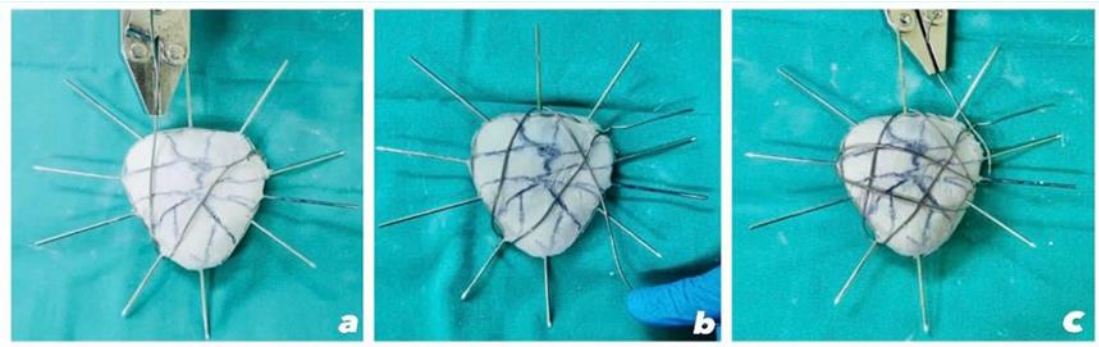


Figure 7

a) The long end of the wire is passed over the patella anteriorly to the corresponding k wire on the other end.
b) This is performed several times creating and anterior cage for stabilization of the central fragments.
c) Once the cage is completed, secure the free end of the cerclage wire to the short end.

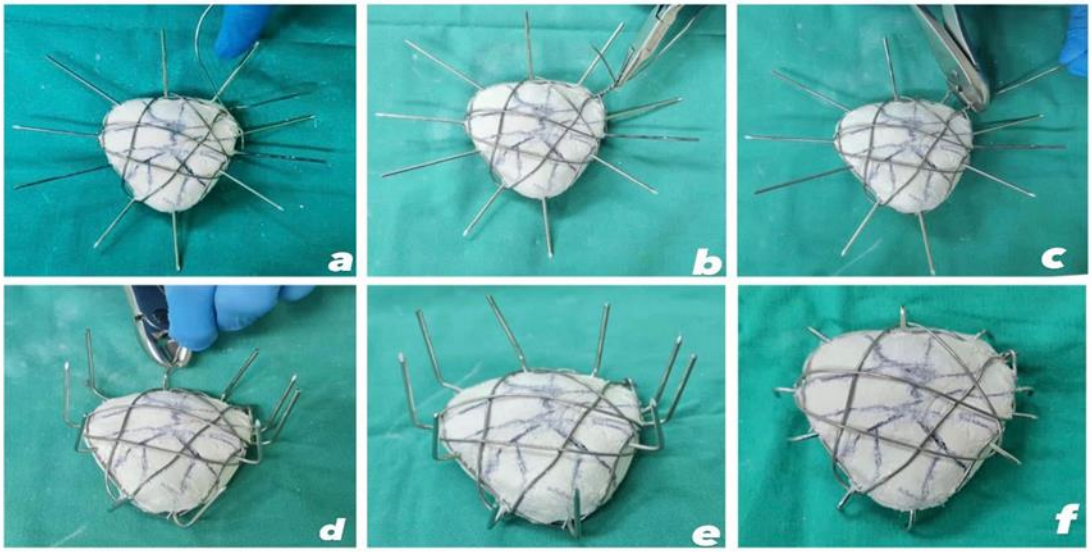


Figure 8

a) Merge the wire with the short end.
b) Cautious wire twisting and tightening to prevent alteration of construct
c) Cut the ends and embed them posteriorly
d) Bend all the k wire tips anteriorly at a 90 degree angle
e) Cut the tips to approximately 1cm
f) Rotate them posteriorly to prevent migration of the cage construct.

**Removal Surgery**

Removal surgery is fairly straightforward. After adequate exposure is obtained longitudinal wires are identified at one end and cut. they can then be removed from their opposite end. Once all longitudinal wires are removed the cerclage cage can then be removed in its entirety by removing any fibrous tissue overlying it.

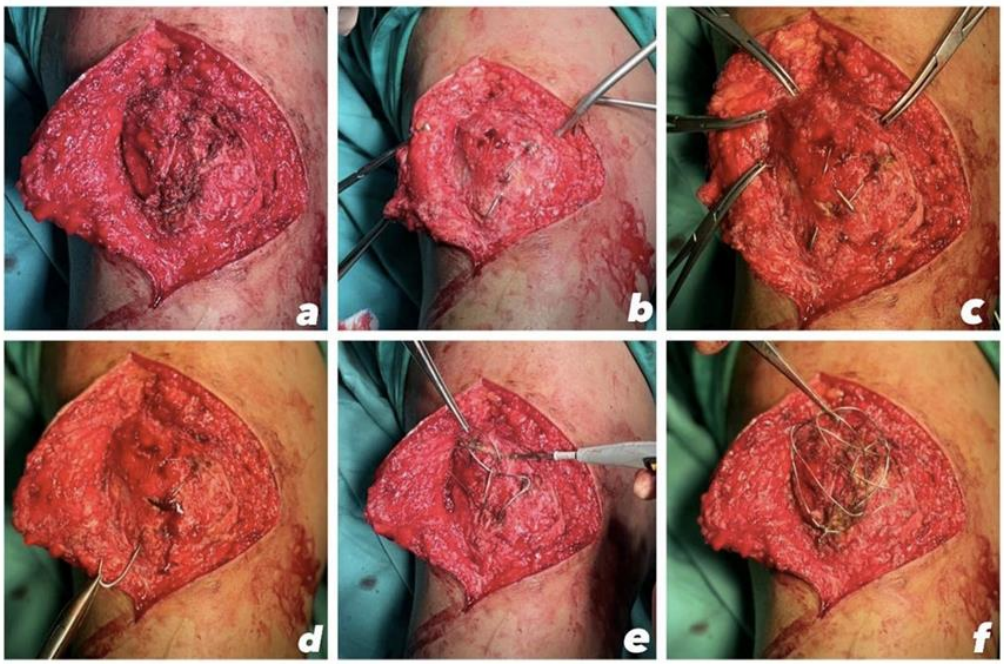


Figure 9: Removal steps

a) Central patella incision explores: in this case we had gone through the old incision
b) Identify the anterior stellate k-wires
c) Cut on end of the wires
d) Remove the contralateral end with a playar
e) Diathermize along the anterior cage's cerclage wires
f) En-mass removal of the cage (encapping)


Figure 10: Post removal

a) Implant removed, off the patella
b) Anterior view post removal in knee flexion
c) Anterior view post removal in knee extension

## DISCUSSION

Patella fractures are comprised of injuries ranging from subtle non-displaced fractures to open comminuted fractures with significant bone loss, most commonly caused by direct trauma or a compressive force, or indirectly due to contraction of quadriceps or excessive stress to the extensor mechanism. [11][12] Priority in treatment is attainment of anatomic reduction while utilising a fixation method that maximizes stability with minimal hardware prominence. [11]

Comminuted patella fractures are among the most challenging clinical problems in Orthopaedics. Treatment aims to restore the integrity of the extensor mechanism and the congruity of patellofemoral joint. [13] Ideal fixation methods are still fiercely debated, with modified tension band and its variations being the treatment of choice for most surgeons, with patellectomy (partial or total) being the preference when anatomical reduction of the displaced bone fragments is not possible. [14]

The original Himawari technique is superior to a simple cerclage in two ways. It provides individual fragment stability with the transverse wires while providing anterior stability via anterior winding. However, it requires the use of expensive locking sleeves to crimp the cerclage wires. By doing away with the locking sleeves, our modification allowed us to achieve stability and compression of the fragments at a significantly reduced cost.

## CONCLUSION

This case illustrates that fixation of comminuted patella fractures are achievable with low cost and basic equipment available, making it a feasible option for more rural or impoverished populations. This gives them another option before having to resort to salvage procedures such as patellectomies.

## REFERENCES


1. "Himawari"method for comminuted patellar fractrure, YouTube; http://www.youtube.com/watch?v=lXeziL11bBw
2. Treatments of Patella Fracture, Slideshare; http://www.slideshare.net/kumaramitphysio/treatment-of-patellar-fracture
3. Kazuha Kizaki, Soshi Uchida et al. Surgical Management with Self-Locking Pins and Circumferential Wiring for Treating Comminuted Patella Fractures Achieved Seiza-Style Sitting. [Joints] 2019 Dec; 7(4): 218-221
4. Lotke PA, Ecker ML et al. Transverse fractures of the patella. Clin Orthop. 1981; 158: 180 – 184.
5. Wild M, Windolf J, Flohé S. Patellafrakturen. [Fractures of the patella]. *Unfallchirurg.* 2010 May;113(5):401–411. doi: 10.1007/s00113-010-1768-x. (Ger).
6. Matsuo T, Watari T, Naito K, Mogami A, Kaneko K and Obayashi O. Percutaneous cerclage wiring for the surgical treatment of displaced patella fractures. Strategies Trauma Limb Reconstr 2014; 9: 19-23
7. Lazaro LE, Wellman DS, Sauro G, Pardee NC, Berkes MB, Little MT, Nguyen JT, Helfet DL, Lorich DG. Outcomes after operative fixation of complete articular patellar fractures: assessment of functional impairment. *J Bone Joint Surg Am.* 2013 Jul;95(14):e96 1–e96 8. doi: 10.2106/JBJS.L.00012.
8. Müller EJ, Wick M, Muhr G. Patellektomie nach Trauma-beeinflusst der Zeitpunkt das Ergebnis. [Patellectomy after trauma: is there a correlation between the timing and the clinical outcome]. *Unfallchirurg.* 2003 Dec;106(12):1016–1019. doi: 10.1007/s00113-003-0690-x.
9. Watson-Jones R. Excision of patella. *Br Med J.* 1945;2:195. doi: 10.1136/bmj.2.4414.195-a. Available from: http://dx.doi.org/10.1136/bmj.2.4414.195-a.
10. Heineck AP. The modern operative treatment of fractures of the patella. *Surg Gynecol Obstet.* 1909;9:177–248.
11. Schuett DJ, Hake ME, Mauffrey C, Hammerberg EM, Stahel PF, Hak DJ. Current treatment strategies for patella fractures. Orthopedics. 2015;38(6):377-84.

12. Frobell R, Cooper R, Morris H, Arendt, H. Acute knee injuries. In: Brukner P, Bahr R, Blair S, Cook J, Crossley K, McConnell J, McCrory P, Noakes T, Khan K. Clinical Sports Medicine: 4th edition. Sydney: McGraw-Hill. p.626-683.
13. Kfuri M, Escalante I, Schopper C, et al. Comminuted patellar fractures: The role of biplanar fixed angle plate constructs. Journal of Orthopaedic Translation. 2021;27:17-24.
14. Reudi TP, Murphy WM. AO Principles of Fracture Management. New York, NY: Thieme-Stuttgart, 2000: 483-91.
15. Masanori H, Haruhiko T, Hiroshi N. Clinical results of “himawari methods” using self-locking pin and cerclage wiring for patella fractures. 中国・四国整形外科学会雑誌. 2020;32(1):137-141.
16. Sutton FS, Thompson CH, Lipke J, Kettelkamp DB. The effect of patellectomy on knee function. J Bone Joint Surg Am. 1976;58(4):537-540.